



Lecture Code : PG02-S3

Session Name : PG Education 2 (Glomerular Disease)

Session Topic : Practical Point of View to Manage Podocytopathies

Date & Time, Place : June 19 (Thu) / 10:30-12:00 / Room 2 (GBR 102)

## Case Presentation 2: Focal Segmental Glomerulosclerosis, Misdiagnosed as Minimal Change Lesion at Initial Biopsy

**Ho Jun Chin**

*Seoul National University College of Medicine, Republic of Korea*

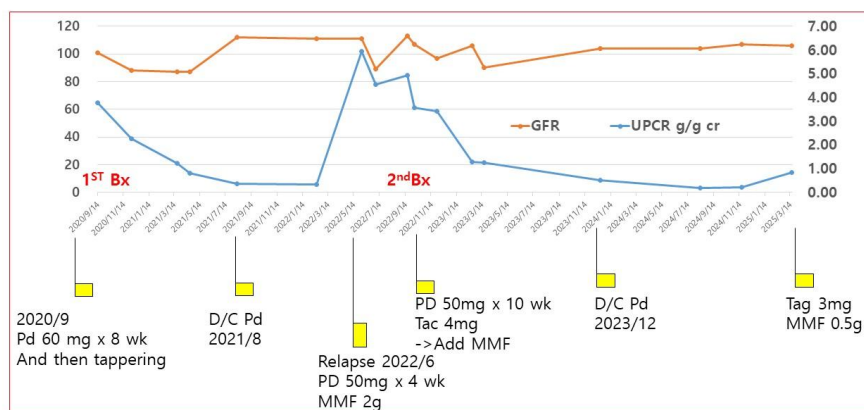
Case 1: A patient with nephrotic proteinuria was transferred with no response to high dose steroid treatment. Minimal change lesion was presumed with renal biopsy. She got another renal biopsy after transfer and confirmed renal disease as FSGS. Case 2: A patient with non-nephrotic ranged proteinuria had renal biopsy confirmed as obese related FSGS.

**Keywords:** fsgs, minimal change lesion, treatment, obesity, secondary fsgs

PRIMARY FSGS\_PPT.jpg

Sum>

◆ 부작용 : None



PRIMARY FSGS\_PPT.jpg

▪ BMI, GFR, and UPCR

