

Abstract Submission No.: A-1339

Use of Focused Cardiac Ultrasound to Verify the Tip Location of Central Venous Catheter During Hemodialysis

Wonho Park, Ji-Young Ryu, Jang-Won Seo, Seon Ha Baek, Ja-Ryong Koo, **EunJung Kim**
Department of Internal Medicine-Nephrology, Dongtan Sacred Heart Hospital, Korea, Republic of

Case Study : The precision of central venous catheter placement is critical for the safety and effectiveness of hemodialysis. This case report delineates the application of focused cardiac ultrasound (FoCUS) in validating the accurate positioning of a central venous catheter tip during hemodialysis treatments. A 41-year-old male with a medical history of Type 2 diabetes mellitus, hypertension, diabetic retinopathy, and hyperthyroidism was hospitalized to commence hemodialysis. The central venous catheter was placed in the right internal jugular vein, with the initial tip placement in the mid-right atrium. Hemodialysis was performed uneventfully with this permanent catheter. Nonetheless, routine echocardiography detected the catheter tip within the tricuspid valve of the right ventricle (RV), prompting the echocardiography team to recommend potential repositioning. Notwithstanding, chest PA radiography displayed stability in tip position post-insertion (Figure 1A). Contrastingly, FoCUS in the left lateral decubitus position revealed malpositioning of the catheter tip within the RV tricuspid valve (Figures 1B and 1C). Further FoCUS assessments while the patient was supine during dialysis confirmed the catheter tip's proper placement within the right atrium (RA) (Figures 2A and 2B), as substantiated by RV-focused and apical four-chamber views. This demonstrated the tip's deep and appropriate location within the RA, negating the need for repositioning. This case accentuates the indispensable role of FoCUS in verifying the precise localization of central venous catheter tips in patients undergoing hemodialysis. This case also observed that the catheter tip's position is susceptible to change with variations in patient posture. FoCUS emerges as a non-invasive, dependable technique for the real-time determination of catheter tip placement, thereby guiding clinical decision-making and augmenting patient safety and therapeutic efficacy.

Figure 1 Focus.jpg

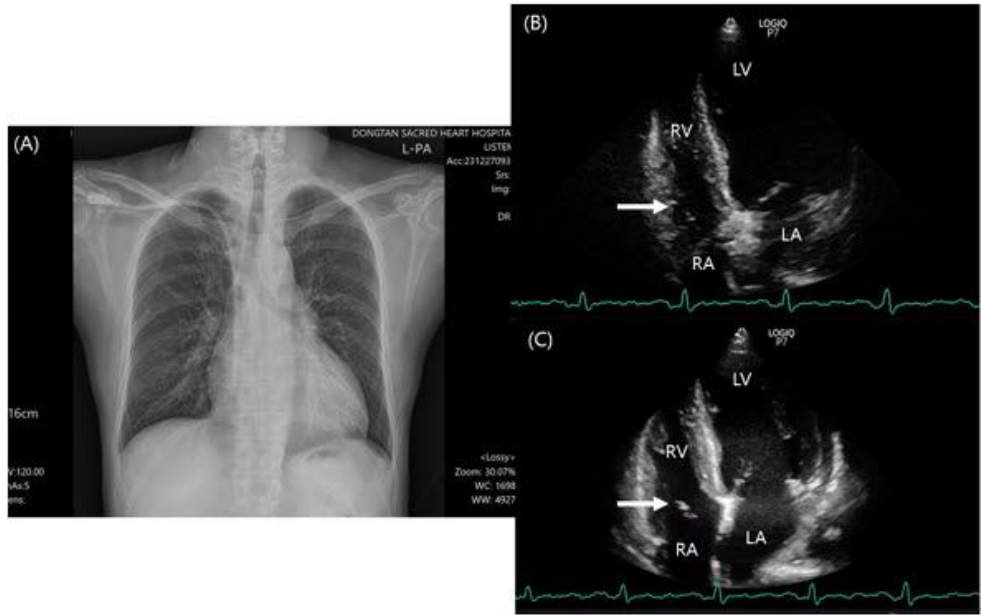


Figure 1 Focus.jpg

