

Abstract Type : Oral

Abstract Submission No. : OR-1500

Scintigraphic Evaluation of Renoprotective Effects of Coenzyme Q10 in a Rat Renal Ischemia-Reperfusion Injury

Aylin AKBULUT¹, Bugra Keseroglu², Gokhan Koca¹, Hatice Surer³, Elmas Ogus³, Nihat Yumusak⁴, Cem Nedim Yuceturk², Berat Cem Ozgur², Meliha Korkmaz¹

¹Department of Nuclear Medicine, Ankara Training and Application Hospital, University of Health Sciences, Turkey

²Department of Urology, Ankara Training and Application Hospital, University of Health Sciences, Turkey

³Department of Biochemistry, Ankara Training and Application Hospital, University of Health Sciences, Turkey

⁴Department of Pathology, Faculty of Veterinary , University of Harran, Turkey

Objectives: Renal ischemia-reperfusion injury (RIRI) may occur secondary to various reasons and may lead to acute or chronic renal failure. Coenzyme Q10 (CoQ10) is a well-known anti-oxidant that has been assessed in a variety of diseases due to oxidative stress and decreased antioxidant capacity. Still, the effects CoQ10 against RIRI have not been evaluated. Our aim was to evaluate the protective effects of CoQ10 to renal ischemia-reperfusion by biochemical, immunohistochemical and scintigraphic findings.

Methods: 30 Wistar albino rats were randomly separated into three groups of 10; Group Sham; Group ischemia-reperfusion (IR) underwent renal ischemia by left renal pedicle clamping, and Group CoQ10+IR received CoQ10 and underwent IR. 24 hours later after the reperfusion, scintigraphy was performed in all groups before sacrifice. To demonstrate the effects of RIRI, serum urea and creatinine levels and tissue levels of malondialdehyde (MDA), total sulphidile (SH), total nitrite, nitrate and myeloperoxidase (MPO) markers of oxidative stress were evaluated. Both kidneys were subjected to histopathological evaluation and besides; to confirm RIRI induced immunohistochemical aspects of apoptosis TUNEL assay method and activated caspase-3 were assessed.

Results: The tissue oxidative stress levels, histopathologic changes, apoptosis scores and quantitative scintigraphic parameters were significantly higher in Group IR compared to Group Sham. Though tissue oxidative stress levels and histopathologic changes were not significant the quantitative scintigraphic parameters of the contralateral non-ischemic kidney of Group IR were significantly increased. Compared to Group IR, Group CoQ10+IR presented decreased tissue oxidative stress levels; decreased scores of histopathology and apoptosis, and decreased quantitative scintigraphic parameters with increased SRF in ischemic kidney.

Conclusions: Our results suggest that other than its anti-oxidant properties, CoQ10 shows anti-peroxidative, anti-apoptotic and anti-inflammatory potential in protecting the renal functioning of the ischemic kidney. Furthermore our results show that renal scintigraphy is a feasible method to detect early changes in renal functioning after RIRI.

Figure 1. Photomicrograph of Group Sham, showing negative immunoreaction (A), Group IR with immunopositive reaction (B), Group CoQ10+IR showing weak immunopositive reaction in caspase-3. Photomicrograph of Group Sham showing negative immunoreaction (D), Group IR showing severe

apoptosis with red nucleus positivity (E), Group CoQ10+IR showing weak apoptosis with few red nucleus positivity (F) in TU

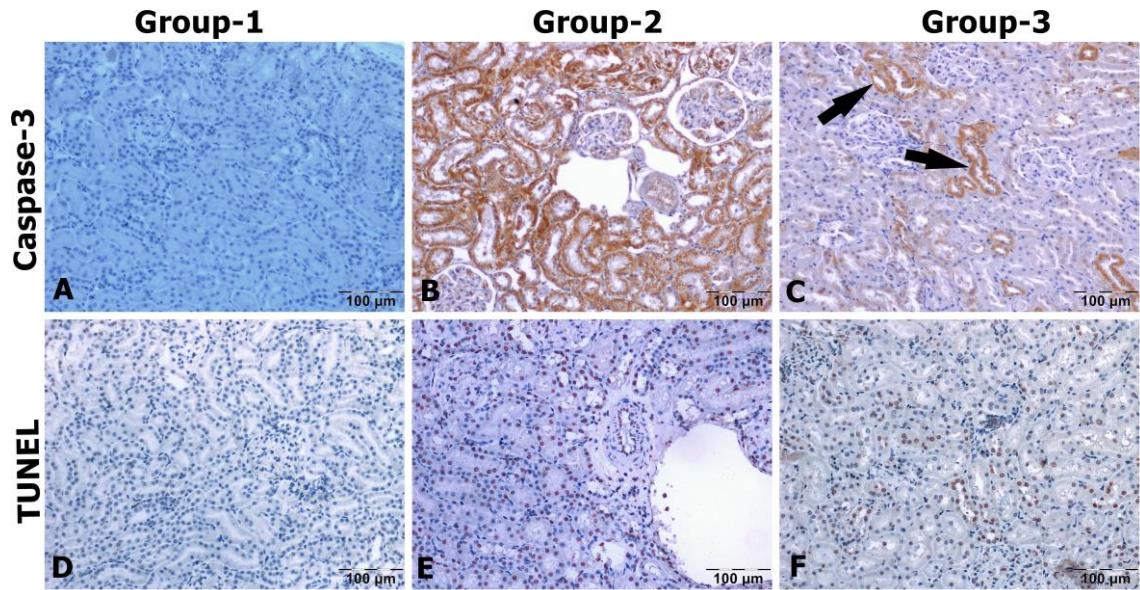


Figure 2. The mean \pm 1 standard deviation of MDA, MPO, total nitrite, nitrate and SH levels of the groups are presented in graphics.

