

Abstract Type : Oral

Abstract Submission No. : OR-1309

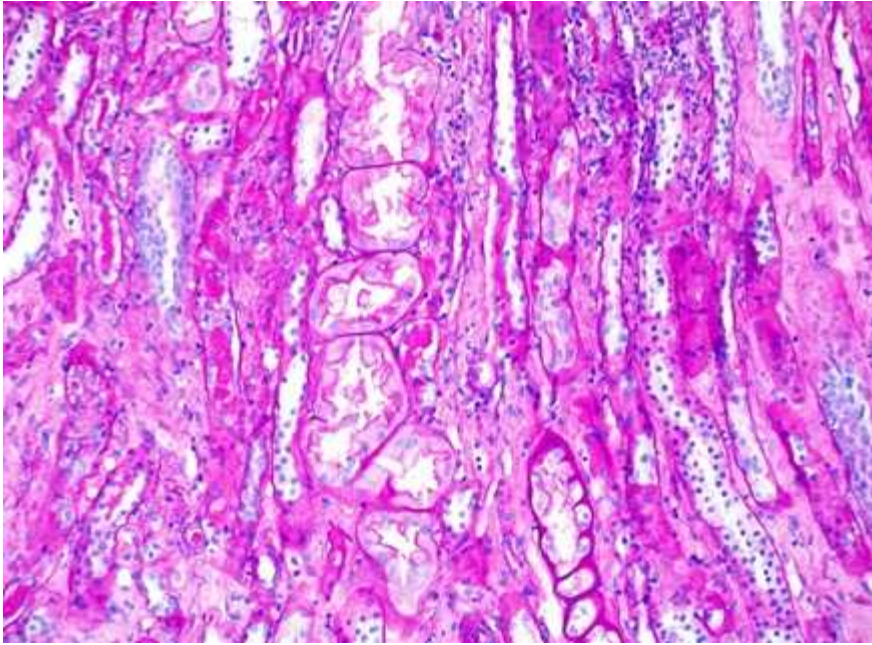
A severe case of tenofovir-associated acute kidney injury requiring hemodialysis in a patient with chronic B hepatitis

Ji Hye Lim, Kwang Young Lee

Department of Internal Medicine-Nephrology, Presbyterian Medical Center, Korea, Republic of

Case Study: A 55-year-old Korean man presented with general weakness and lower extremity edema. He was an HBeAg-negative chronic hepatitis B (CHB) patient and had been prescribed a daily dose of 300 mg of Tenofovir disoproxil fumarate (TDF) for 18 months at a local clinic. Before starting TDF, his serum creatinine level was 1.2 mg/dL. He had also been prescribed 50 mg of losartan daily for 1 year due to hypertension. On admission, he had a temperature of 36.3°C, pulse rate of 76 beats per minute, blood pressure of 110/80 mmHg, and respiratory rate of 20 breaths per minute. His lower extremities demonstrated Grade 2 pretibial pitting edema. Both kidneys had normal dimensions (right kidney, 11.0 cm × 5.8 cm; left kidney, 11.5 cm × 5.2 cm). The blood urea nitrogen and serum creatinine concentrations were 92 mg/dL and 15.7 mg/dL, respectively. His serum creatinine concentration 3 months earlier was 1.5 mg/dL. Initial arterial blood gas analysis revealed severe metabolic acidosis (pH = 7.190, pCO₂ = 25.0 mmHg, and HCO₃⁻ = 9.5 mmol/L). His fractional excretion of sodium was 11.3%. Urinalysis showed increased β₂-microglobulinuria level and a positive urinary anion gap. The patient also had proteinuria, hematuria, and glycosuria. Electrophoresis of the serum and urine was negative for monoclonal gammopathy. Under the clinical impression of acute kidney injury (AKI) with metabolic acidosis, hemodialysis was initiated. On day 38, percutaneous renal biopsy was performed, and the findings indicated a severe degree of acute tubular necrosis and tubulointerstitial inflammation. Electron microscopy revealed effacement of podocyte foot processes within proximal tubular cells. The patient was subsequently switched to entecavir and showed subsequent gradual improvement in renal function. Thus, hemodialysis was discontinued 1 month after admission. At the 6-month follow-up, serum creatinine levels had decreased to 2.5 mg/dL, and his glycosuria and hematuria disappeared.

Figure(A) Light microscopy showed severe acute tubular necrosis with cytoplasm reduction, loss of brush border, and luminal ectasia (hematoxylin and eosin, x200 magnification). 1.



Foot process effacement of the podocytes within a proximal tubular epithelial cell were observed on electron microscopy.

