

**Abstract Submission No. : 2171**

## **Bevacizumab-induced glomerular microangiopathy: experience of two clinical cases**

**Wanhee Lee**, Hyo Jin Kim, Sang Heon Song, Eun Young Seong, Harin Rhee, Da Woon Kim, Hakeong Jeon, Sungmi Kim  
Department of Internal Medicine-Nephrology, Pusan National University Hospital, Korea, Republic of

### **Case Study: Introduction:**

Bevacizumab is a monoclonal antibody against vascular endothelial growth factor used to treat various types of cancers. However, it can be associated with adverse outcomes such as hypertension and proteinuria. We report two cases of thrombotic microangiopathy (TMA) associated with the use of bevacizumab.

### **Cases:**

A 58-year-old woman with a history of right ovarian carcinoma was referred to nephrology due to edema and two-positive proteinuria on a urine dipstick test. After the third course of bevacizumab, blood pressure was elevated and proteinuria increased from 278 mg/g to 2390 mg/g. After the fourth course of bevacizumab, proteinuria increased substantially to 4859 mg/g. The patient showed worsening edema of her hands, legs, and face. Renal biopsy showed glomerular endotheliosis containing fluffy material and widely foot process effacement (Figure 1). Bevacizumab chemotherapy was stopped. One month after discontinuation of bevacizumab, proteinuria decreased to 1847 mg/g. Another patient was a 71-year-old man with a history of hepatocellular carcinoma and alcoholic liver cirrhosis who was referred to nephrology due to proteinuria more than 2000 mg/day. After that bevacizumab chemotherapy was stopped. Renal biopsy showed that glomerular hyaline thrombi and focal marked foot process effacement. In addition, mesangial interposition with double contour and subendothelial deposits were shown, indicating liver cirrhosis-associated nephropathy (Figure 2). Proteinuria decreased to 138 mg/day after the withdrawal of bevacizumab for approximately 4 months.

**Conclusion:** Bevacizumab could induce glomerular microangiopathy resulting in hypertension, proteinuria, edema, and nephrotic syndrome. Therefore, patients who receive bevacizumab should be monitored carefully during their treatment.

Figure 1. Light microscopy showed glomerular endotheliosis containing fluffy material and electron microscopy showed widely foot process effacement.

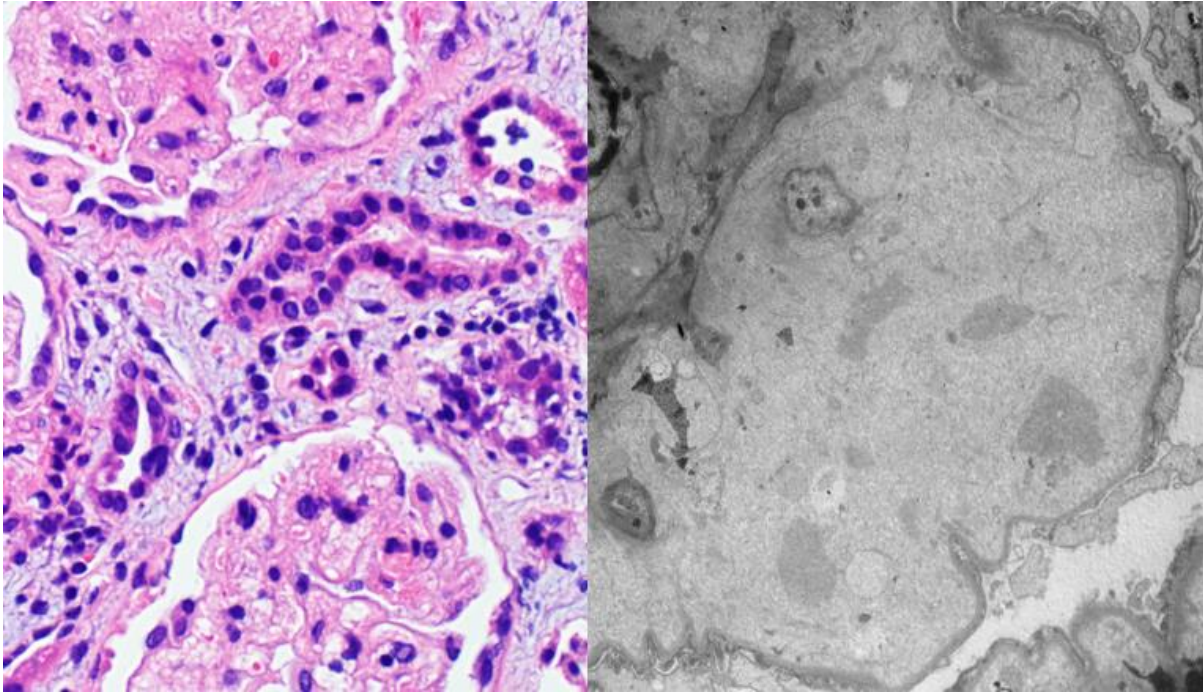


Figure 2. Light microscopy showed glomerular hyaline thrombi and electron microscopy showed widely foot process effacement.

