

**Abstract Submission No. : 1033**

**A case of three Gitelman syndrome patients with chronic hypokalemia from a two-generation family.**

**Ju Hwan Oh**, Kwang Young Lee

Department of Internal Medicine-Nephrology, Presbyterian Medical Center, Korea, Republic of

**Case Study:** Gitelman syndrome (GS) is an autosomal recessive renal tubular disorder associated with genetic mutation of SLC12A3, which codes thiazide-sensitive Na-Cl cotransporter (NCCT) gene, featured by hypokalemic metabolic alkalosis in combination with significant hypomagnesemia and low urinary calcium excretion. Here we report three GS patients with chronic hypokalemia from a two-generation family.

The pedigree of the GS patients is shown in Fig 1. The proband was a 26-year-old Korean woman who visited the emergency room with general weakness and hypokalemia. Laboratory finding demonstrated hypokalemia (2.5mmol/L), hypomagnesemia (1.8mg/dL) and her serum concentration of total CO<sub>2</sub> was 28 mmol/L. Transtubular potassium gradient (TTKG) was 13. The spot urine calcium to creatinine ratio was 0.0057 (mg/mg), indicating hypocalciuria. Her initial vital signs indicated 110/89mmHg, heart rate of 90 beats per minute and respiratory rate of 20 breaths per minute. GS was suspected based on the laboratory results and clinical symptoms. Genetic analysis was performed to identify the causative gene mutation, and SLC12A3 mutation (a homozygous c.1924C>T in exon15) was observed (Fig 2A). Her younger brother (aged 21 years) was enlisted in the military, and a biochemical test after the enlistment revealed hypokalemia, and TTKG was 6. Genetic analysis was also performed on him, and compound heterozygous mutation (a heterozygous c.1924C>T in exon 15 and a heterozygous c.25737T>A in exon 22) was observed (Fig 2B). And their father (aged 59 years) had hypokalemia for several years. Biochemical analysis revealed hypokalemia (3.0 mmol/L) and TTKG was 7.83. Genetic analysis revealed that the father also had the same mutation as his daughter and son. (Fig. 2B). After adequate magnesium and potassium supplementation, these three patients subsequently showed improvement of symptoms and laboratory results, and they are currently being followed on an outpatient basis.

Figure 1. Family tree of our patients with Gitelman syndrome

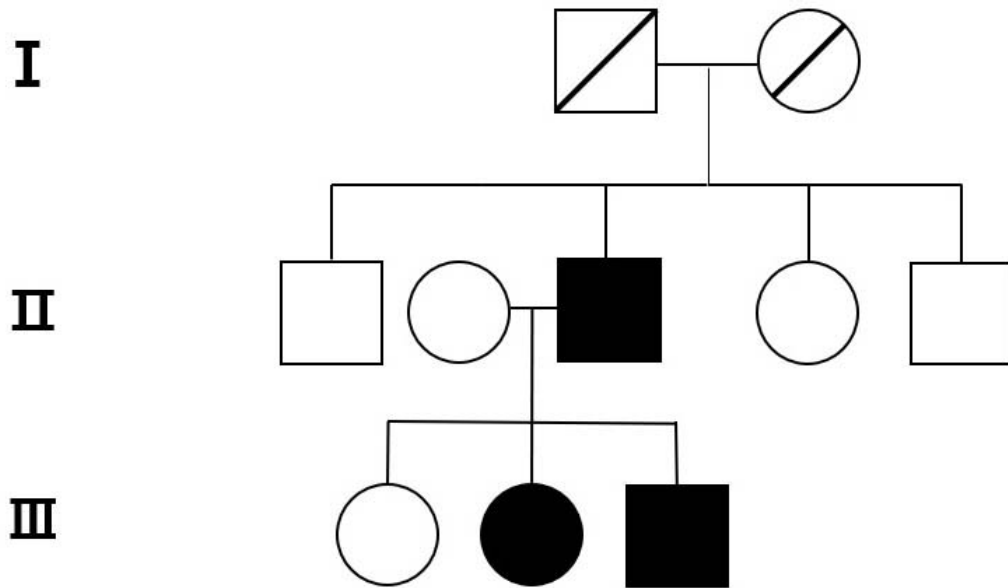


Figure 2. DNA sequence chromatogram of SLC12A3 gene (A) a homozygous c.1924C>T in exon15 (B) a heterozygous c.1924C>T in exon 15 and a heterozygous c.2573T>A in exon 22

