



**Abstract Type : Poster exhibition**

**Abstract Submission No.: A-0288**

**Abstract Topic : Interventional Nephrology**

## **Kinking of a Peripherally Inserted Central Catheter After Bedside Temporary Hemodialysis Catheter Insertion: A Case Report**

**Do Hyoung Kim**<sup>1</sup>, Hyang yun Lee<sup>1</sup>, Hyuk Huh<sup>1</sup>, Hayne Cho Park<sup>1</sup>, Hyung Seok Lee<sup>2</sup>, Eun Jung Kim<sup>3</sup>, Gwangoho Choi<sup>4</sup>, Young-Ki Lee<sup>1</sup>

<sup>1</sup>Department of Internal Medicine-Nephrology, Kangnam Sacred Heart Hospital, Korea, Republic of

<sup>2</sup>Department of Internal Medicine-Nephrology, Hallym University Sacred Heart Hospital, Korea, Republic of

<sup>3</sup>Department of Internal Medicine-Nephrology, Dongtan Sacred Heart Hospital, Korea, Republic of

<sup>4</sup>Department of Internal Medicine-Nephrology, Chuncheon Sacred Heart Hospital, Korea, Republic of

**Case Study :** Background: Insertion of a dialysis catheter is a core procedure of nephrology practice. While urgent dialysis may be life-saving, mechanical and infectious complications related to the insertion of temporary dialysis catheter can be fatal. We report a case in which a peripherally inserted central catheter (PICC) was kinked after bedside temporary hemodialysis catheter insertion in a patient requiring urgent continuous renal replacement therapy. Case: An 84-year-old male patient with end-stage renal disease (ESRD) receiving hemodialysis through a left radio-cephalic arteriovenous fistula was admitted to the orthopedic department for the treatment of lumbar spine spondylolisthesis. During hospitalization, he required intravenous drug administration, for which a PICC was placed via the right basilic vein. (Figure 1) The patient subsequently developed pneumonia and experienced respiratory distress with hypotension, necessitating transfer to the intensive care unit. For emergency continuous renal replacement therapy, a temporary dialysis catheter was inserted into the right internal jugular vein under ultrasound guidance. Following this intervention, malfunction of the PICC line was observed. Chest radiography revealed kinking of the PICC (Figure 2, Arrow), prompting its removal and replacement with a new PICC line. Conclusion: PICC dysfunction can result from mechanical complications such as kinking, thrombosis, or malposition. In critically ill patients, especially those requiring multiple vascular access devices, the risk of catheter malfunction increases. This case underscores the importance of regular monitoring of catheter function, appropriate imaging to assess placement and integrity, and timely intervention to prevent complications related to intravenous access.

Figure1\_PICC\_Kink\_Case.png

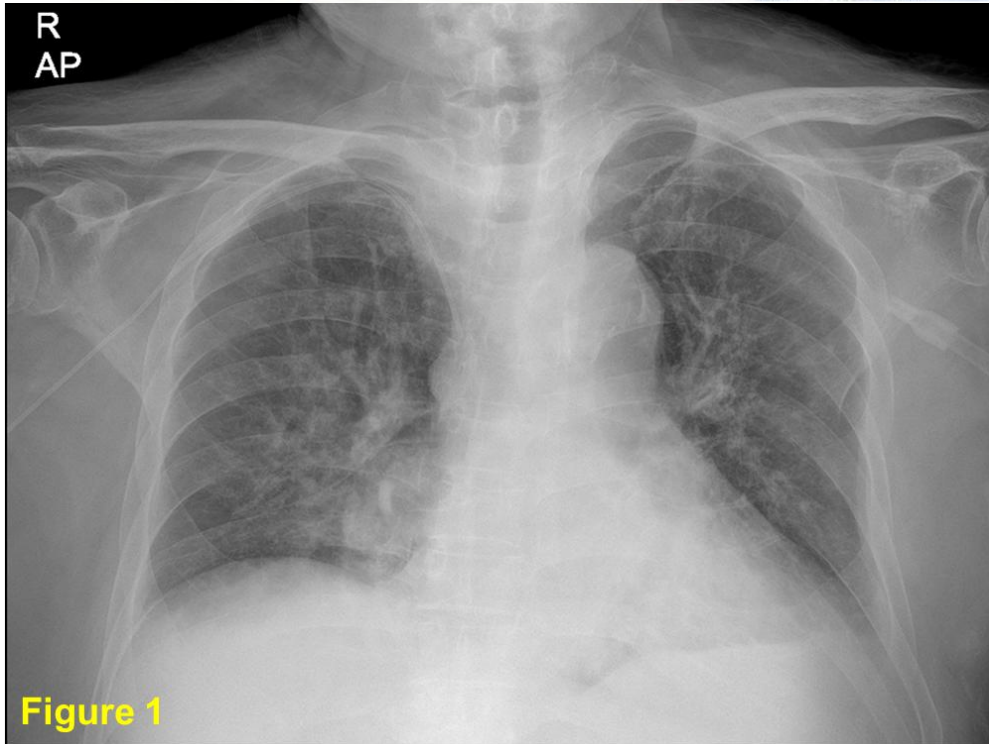


Figure1\_PICC Kink Case.png

