

Abstract Submission No. : 2274

Peripheral Arterial Occlusive Disease in the Vascular Access Arm

Hansae Kim

Department of Internal Medicine-Nephrology, Q hospital, Korea, Republic of

Case Study: Peripheral arterial occlusive disease(PAOD) is common in patients with end stage renal disease(ESRD). Atherosclerosis reduces the internal diameter of the blood vessels, resulting in ischemic symptoms. Especially PAOD in hemodialysis vascular access(VA) reduces arterial blood flow and worsens symptoms. We report a case of PAOD on the ipsilateral side of arteriovenous fistula treated with percutaneous transluminal angioplasty(PTA) in a patient with ESRD. A 57-year-old man with diabetic ESRD underwent left brachiocephalic fistula creation. He presented with painful swelling and multiple wounds of the fingers on the ipsilateral side of the VA. He took narcotic analgesics for severe pain, but it didn't work. In addition, multiple fingertip wounds persisted despite topical dressing and antibiotics treatment. Blood flow rate in the VA measured by Doppler ultrasound was 1100 mL/min. Fistulogram showed juxta-anastomotic stenosis. Arteriogram revealed calcifications and multiple stenoses from the brachial artery to the palmar arch(Figure 1). Balloon dilatation was performed on both sides of the radial artery and ulnar artery. The 5Fr sheath was inserted through the brachial artery approach. A 0.014 HydroST wire was inserted through Sheath and a 2 mm * 4 cm catheter (Medtronic Vascular, Santa Rosa, CA, USA) was ballooned to the distal part 90% stenotic lesion of the ulnar artery for up to 15 atm for 3 minutes. Afterward, a 2 mm * 15 cm balloon catheter was inserted into the radial artery and maintained at 8 atm for 2 minutes(Figure 2). During deflation, the pressure was slowly lowered to prevent blood vessel rupture, maintained at 5 atm for 30 seconds, and then completely removed. Stenosis was not observed and improvement of blood flow was confirmed. The procedure was terminated. Symptoms such as pain and delayed wound healing due to PAOD in the fistula arm can be effectively treated with PTA.

Figure 1. Multiple stenoses of radial and ulnar artery

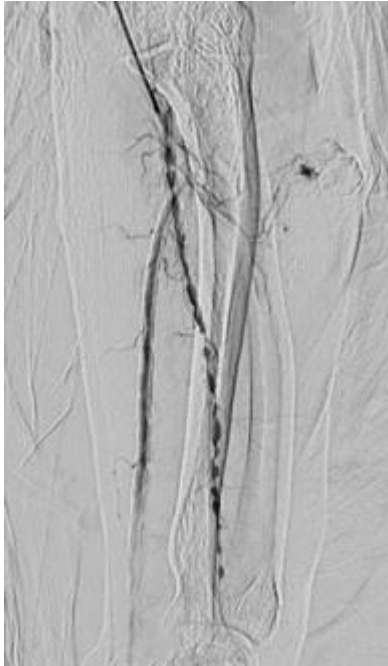


Figure 2. PTA of the radial artery

