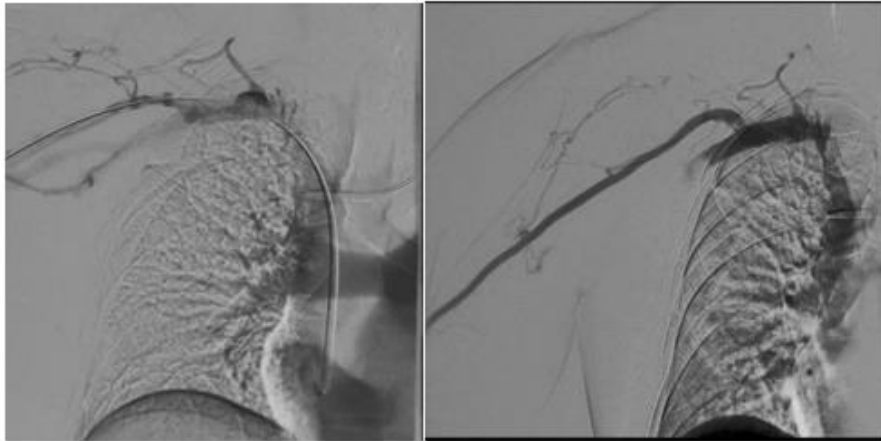


Abstract Submission No.: A-1231**Clinical and Blood Flow Improvement in Chronic Kidney Disease Patient on Hemodialysis with Central Venous Stenosis after Angioplasty Procedure: a Case Report****Arlentina Bentivolia Simamora¹**, Atma Gunawan¹¹Department of Internal Medicine, Universitas Brawijaya, Indonesia²Department of Internal Medicine, Division of Nephrology and Hypertension Universitas Brawijaya, Universitas Brawijaya, Indonesia

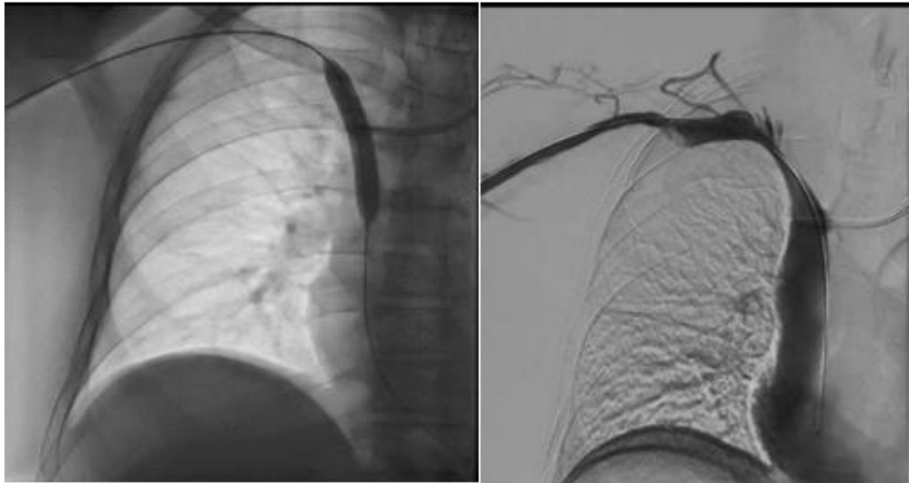Case Study : Background: Chronic Kidney Disease (CKD) is characterized by an irreversible kidney function. The American Society of Nephrology Data in 2019 represented therapy for CKD patients was 63.7% hemodialysis. Research show the use of intravascular access or Central Venous Catheters (CVC) as hemodialysis (HD) mostly causes peripheral venous hypertension which is related to the process of Central Venous Stenosis (CVS). Case: A 63-year-old male patient complaints of pain and swollen right arm since 3 weeks before admission. Malfunction of CVC dialysis since 5 days before, the patient using AV-fistula (AVF), but in the next day, the AVF was also malfunction. From the physical examination, we found swollen dextra superior extremity with increasing size of arm circumference, painful, the bruit and thrill were palpated weakly. Laboratory obtained Hb 7.5 g/ dl with eGFR 9.3270 mL/ min / 1.73m², D-dimer (2.02 mg / dl) and decrease of blood vessel flow. We performed stenosis in the innominate vein from angiography result. Results: Stenosis was found in the innominate vein, there is no stenosis/ occlusion in the blood vessels around the AVF, the balloon was inserted and expanded, a re-evaluation of the blood vessels post ballon insertion was found to still have 50% stenosis (target 25%), in the balloon there was stewing in the stenosis lesion, stenting was not carried out and anti-platelet administration was continued. There was clinical improvement and blood vessel flow. Flow vein increase up to 501 ml/ min ; Inflow 245.23 ml/ min increase up to 640 ml/ min , with increasing vein diameter from 0.53 cm to 0.61cm, reduced arm circumference, reduced pain, of CVC dialysis and AV-fistula can be reused Conclusion: The combination of angioplasty and stent placement is indicated for elastic central vein lesions or if there is dilated stenosis within a 3-month period with good clinical outcomes.

Screenshot (1125).png



(a)

(b)



(c)

(d)

