

Abstract Submission No.: A-0188

Severe Left Ventricular Dysfunction After Flow Reduction Operation For High-flow Fistula In A Hemodialysis Patient And Recovery Trajectory Of 3years

Narae Joo¹, Hyundong Lee²

¹Department of Internal Medicine-Nephrology, Hanmaeum Hospital, Korea, Republic of

²Department of Surgery, Hanmaeum Hospital, Korea, Republic of

Case Study : A 65-year-old male hemodialysis (HD) patient visited a vascular access center due to a high-flow fistula. The flow volume (FV) of arteriovenous fistula (AVF) was 4,450 ml/min, and it was reduced to 1,114 ml/min via flow reduction surgery. After 12 hours of the operation, new onset dyspnea of the New York Heart Association class IV occurred. The ejection fraction (EF) was 24% in transthoracic echocardiography (TTE), which was markedly decreased compared to EF ($\geq 50\%$) of the TTE examined before the surgical revision. The symptoms and radiologic findings were improved by increasing ultrafiltration during HD and reducing afterload with angiotensin receptor antagonist(Figure1). The EF gradually restored to 32% in followed TTE at 2months and more improved by 44% at 1year. As a result of follow-up observation of cardiac function with TTE performed annually for the next 3 years, EF did not change significantly after 1year, but factors such as LV mass index and Fractional shortening showed improvement until 2 years. There was no significant difference between the 2nd year results and the 3rd year results in TTE. These observations suggest that myocardial remodeling due to changes in AVF blood flow is could be continued up to 2 years after the correction(Figure 2). At present, the patient is maintaining HD via the AVF of reduced FV without any signs or symptoms of heart failure. Updated guidelines recommend a flow reduction therapy on the grounds that high-flow AVF is associated high cardiac mortality. However, there has been a concern that transient left ventricular (LV) dysfunction may occur immediately after the flow reduction therapy especially in a case with a large amount of flow reduction volume. It stems from abrupt decrease in the LV preload and increment in the afterload, which can promptly lead to LV systolic dysfunction with significant EF reduction.

figure1APCN2024.jpg

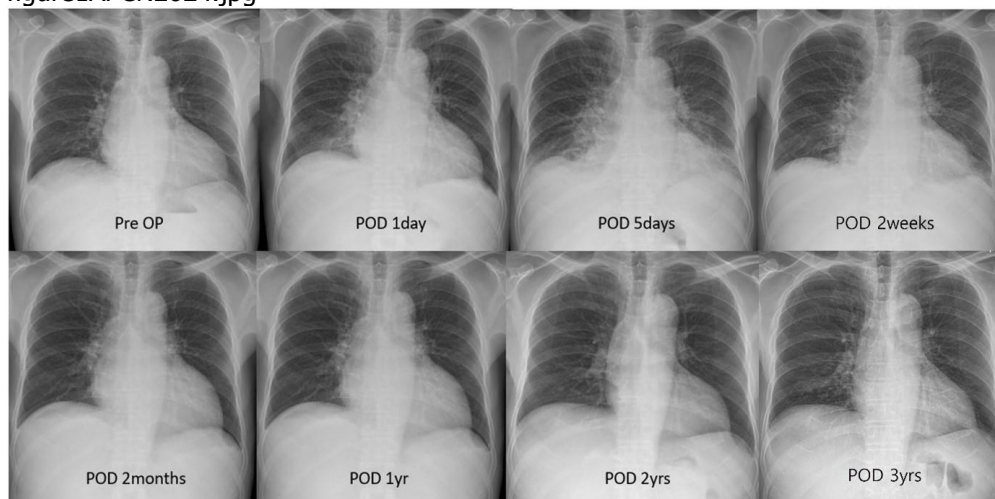


figure1APCN2024.jpg

